

# Central Nervous System Vasculitis

Prof. Hicham El Otmani *MD*

Ibn Rochd University Hospital  
Faculty of Medicine and Pharmacy

Casablanca - Morocco

*hichamotmani@hotmail.com*

**Disclosures: none**

# Learning objectives

- Suggestive situations for CNS vasculitis
  - Clinical manifestations
  - Information given by imaging / CSF
- Stepwise approach for diagnosis:
  - Differential diagnosis (CNS non vascular and CNS non inflammatory vascular pathologies)
  - Diagnostic confirmation (Biopsy if needed)
  - Most frequent causes (with suggestive patterns)
- Therapeutic considerations

# Key-points

- CNS vasculitis is an heterogeneous group of rare diseases characterized by inflammatory lesions of CNS blood vessels
- Etiologies are complexes. CNS Vasculitis can occur in the setting of systemic (infectious or non infectious) vasculitis or can be restricted to the CNS (Primary Angiitis of the Central Nervous System ; PACNS)
- CNS vasculitis is suspected on clinical context, parenchymal and vascular imaging and CSF findings
- Confirmation is obtain by histology (parenchymal and leptomeningeal biopsy). In practice, the majority of situations requiring biopsy concern PACNS
- Exclusion of more frequent differential diagnoses is a key element of diagnostic work-up.
- CNS Vasculitis is still a diagnostic and therapeutic challenge. Multidisciplinary team offer a better opportunities for best management

# CNS vasculitis: Pathophysiology

- Vascular inflammation affecting vessels of different sizes
- Large/medium/small arteries to capillaries (or tiny venules)
- Diminished blood flow ; procoagulant effect of inflammation
  - >>> ischemia, necrosis >>> CNS tissue damage
    - stroke (large/medium vessels)
    - diffuse ischemia (small vessels)
- Vessel wall lesions
  - >>> permanent occlusion (ischemia) / aneurysmal change (rupture/hemorrhage)
- Also, other mechanisms: iatrogenic, infection.....

# Vasculitis: Classification

- **Large vessel vasculitis**

- Giant cell arteritis
  - Takayasu arteritis

- **Medium vessel vasculitis**

- Polyarteritis nodosa
  - Kawasaki disease

- **Small vessel vasculitis**

- Antineutrophil cytoplasmic antibody-associated vasculitis**

- Microscopic polyangiitis
    - Granulomatosis with polyangiitis (Wegener)
    - Eosinophilic granulomatosis with polyangiitis (Churg-Strauss)

- Immune-complex vasculitis

- Cryoglobulinemia
    - IgA vasculitis (Henoch-Schönlein)
    - Hypocomplementemic urticarial vasculitis (anti-C1q)

- **Variable vessel vasculitis**

- Behçet disease**
  - Cogan syndrome

- **Single organ vasculitis**

- Primary angiitis of the central nervous system**

- Nonsystemic peripheral nerve vasculitis
  - Idiopathic aortitis (IgG4)

- **Vasculitis associated with systemic collagen vascular disease**

- Systemic lupus erythematosus**
  - Rheumatoid arthritis vasculitis

- **Vasculitis associated with infection**

- Acute bacterial meningitis

- Mycobacterial tuberculosis**

- Neurosyphilis**

- Lyme neuroborreliosis

- Varicella zoster virus**

- Human immunodeficiency virus type-1/AIDS**

# CNS vasculitis: clinical manifestations

- Presentation is variable, range from acute to insidious
- No clinical manifestation being specific for CNS vasculitis
  - >>>> many differential diagnosis
- Unusual recent headache
- Focal features related to stroke
  - >>>> TIA, Ischemic or hemorrhagic stroke, seizures...
- Symptoms of diffuse neurologic dysfunction
  - >>>> lethargy, confusion, rapidly dementia, psychiatric features.....
- Systemic features such as weight loss, night sweats, fevers...
- Symptoms of (known or unknown) systemic disease (articular, skin, ophthalmic, respiratory....)

# An Update of the Mayo Clinic Cohort of Patients With Adult Primary Central Nervous System Vasculitis

## Description of 163 Patients

Medicine • Volume 94, Number 21, May 2015

Carlo Salvarani, MD, Robert D. Brown Jr, MD, Teresa Christianson, BS, Dylan V. Miller, MD, Caterina Giannini, MD, John Huston III, and Gene G. Hunder, MD

Findings	All Patients (n = 163), n (%)	Biopsy Confirmed (n = 58), n (%)	Angiogram Confirmed (n = 105), n (%)
Headache	97 (59.5)	31 (53.4)	66 (62.9)
Cognitive dysfunction	88 (54)	39 (67.2)	49 (46.7)*
Hemiparesis	66 (40.5)	10 (17.2)	56 (53.3)*
Persistent neurologic deficit or stroke	66 (40.5)	13 (22.4)	53 (50.5)*
Aphasia	40 (24.5)	15 (25.9)	25 (23.8)
Transient ischemic attack	42 (25.8)	9 (15.5)	33 (31.4)*
Ataxia	31 (19)	6 (10.3)	25 (23.8)
Seizures	33 (20.2)	16 (27.6)	17 (16.2)
Visual symptoms (any kind)	61 (37.4)	14 (24.1)	47 (44.8)
Visual field defect	30 (18.4)	5 (8.6)	25 (23.8)*
Diplopia (persistent or transient)	23 (14)	7 (12.1)	16 (15.2)
Blurred vision or decreased visual acuity	18 (11)	3 (5.2)	15 (14.3)
Monocular visual symptoms or amaurosis fugax	2 (1.2)	1 (1.7)	1 (1)
Papilledema	7 (4.3)	4 (6.9)	3 (2.9)
Intracranial hemorrhage	16 (9.8)	5 (8.6)	11 (10.5)
Amnesic syndrome	10 (6.1)	5 (8.6)	5 (4.8)
Paraparesis or quadriparesis	8 (4.9)	5 (8.6)	3 (2.9)
Parkinsonism or extrapyramidal signs	1 (0.6)	0	1 (1)
Constitutional symptoms <sup>†</sup>	15 (9.2)	6 (10.3)	9 (8.6)
Fever	16 (9.8)	8 (13.8)	8 (7.6)

- Persistent neurologic deficit or stroke, headache, and altered cognition were the most common initial symptoms
- These 3 symptoms together were the initial manifestations in 71% of patients
- The combination of 2 or more types of symptoms is very suggestive



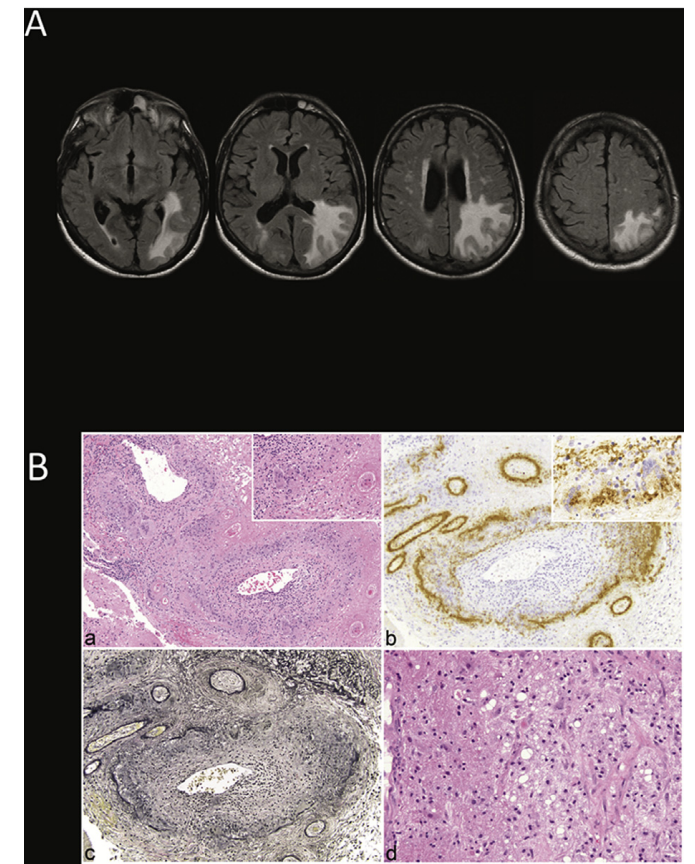
# CNS vasculitis: Other clinicopathological aspects

Journal of Autoimmunity, <https://doi.org/10.1016/j.jaut.2018.10.001>

Primary central nervous system vasculitis mimicking brain tumor:  
Comprehensive analysis of 13 cases from a single institutional cohort of 191  
cases

Carlo Salvarani<sup>a,e,\*</sup>, Robert D. Brown Jr.<sup>a</sup>, Teresa J.H. Christianson<sup>b</sup>, John Huston III<sup>c</sup>,  
Jonathan M. Morris<sup>c</sup>, Caterina Giannini<sup>d</sup>, Gene G. Hunder<sup>f</sup>

- Tumor-like aspect in 13 of 191 (6,8%) patients with the diagnosis of PCNSV (biopsy proven)
- 11/13 granulomatous vasculitis
- More seizures and less vascular events, less angiographic findings and more favorable outcome (Rankin at 0 in 62%)



# CNS vasculitis: Other clinicopathological aspects

J Neurol (2010) 257:1762–1764  
DOI 10.1007/s00415-010-5611-7

LETTER TO THE EDITORS

## Primary angiitis of the CNS with pure spinal cord involvement: a case report

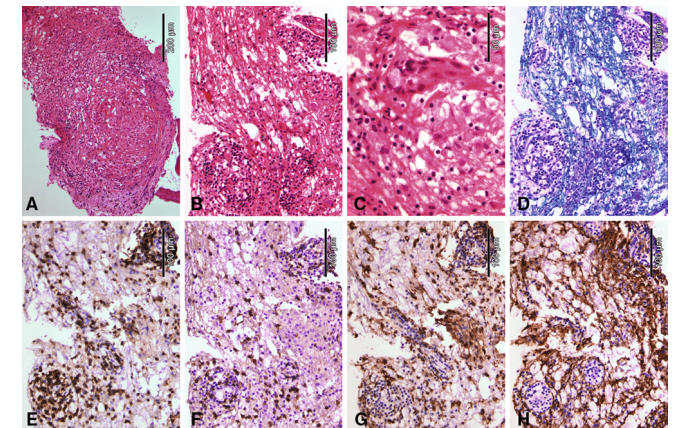
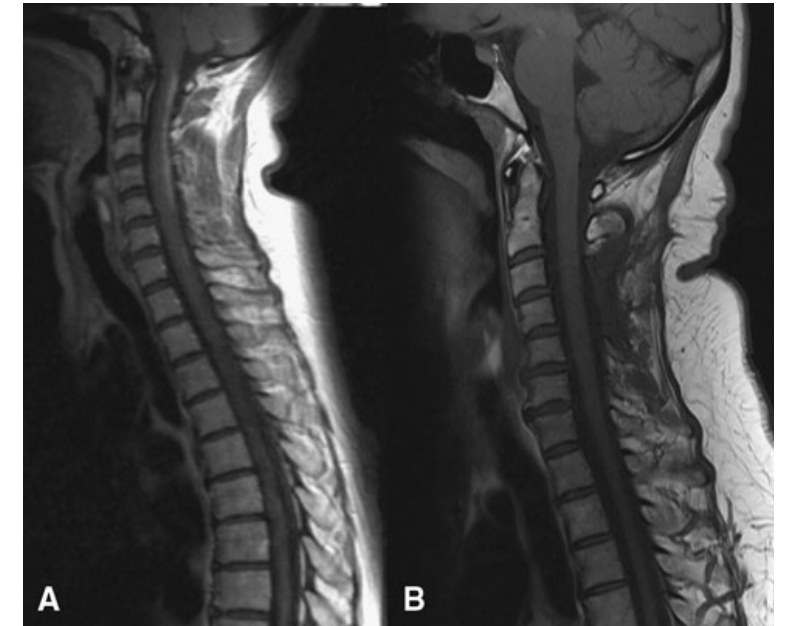
Chantima Goertz · Christiane Wegner ·  
Wolfgang Brück · Peter Berlit

- 44-year-old female, progressive weakness of both legs
- Cervical MRI: Gd-enhancing extensive lesion (normal brain MRI)
- LCS: 12 lymphocytes, no OCB
- Good outcome after CTC pulse but relapse
- Biopsy: granulomatous vasculitis
- Literature:

>>>> Spinal symptoms are a rare presentation of primary CNS vasculitis

>>>> Usually, symptoms (progressive paraparesis and dysesthesia) occur in

the course of the disease (very rare at disease onset or as the only manifestation)



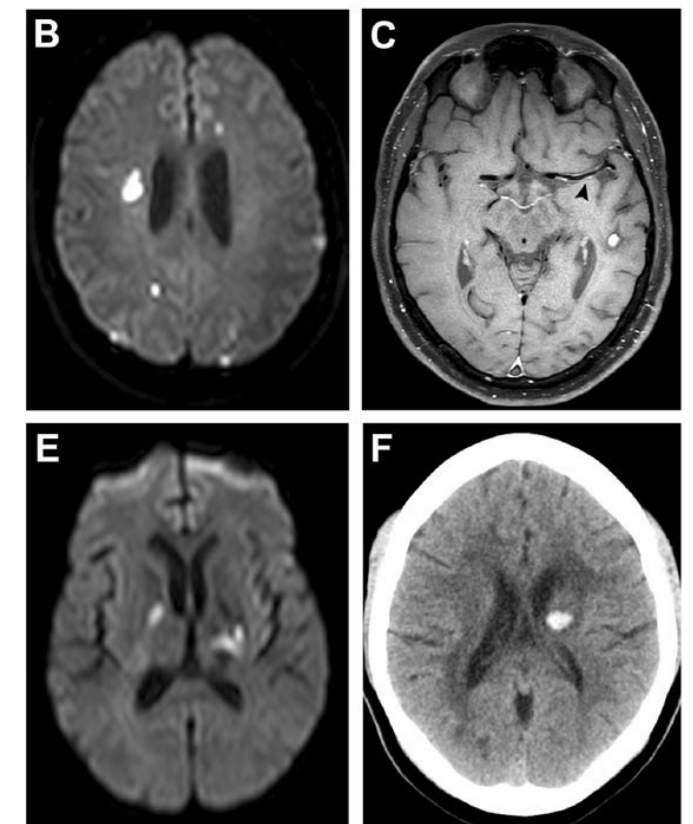
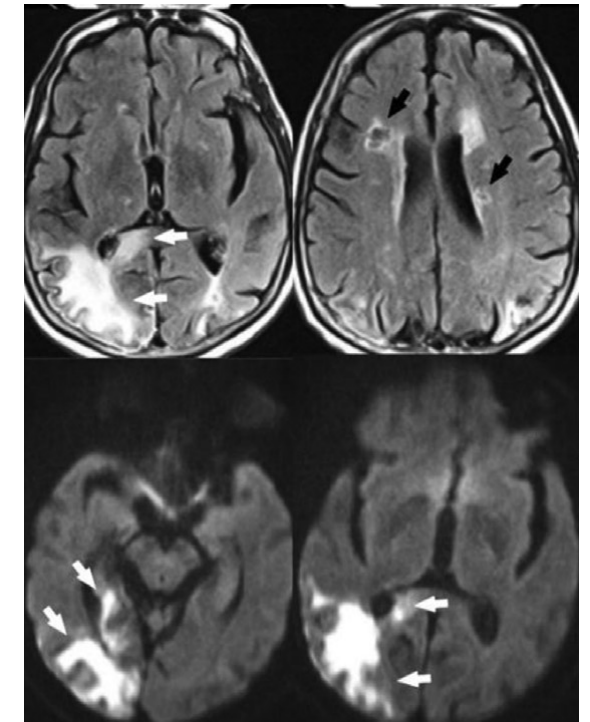
# CNS vasculitis: Neuroimaging

- Neuroimaging plays a vital role in the diagnosis (and follow) of primary and secondary vasculitic disorders
- There are multiplicity of neuroimaging options available (CT-scan, MRI, digital angiography, nuclear medicine) to image:
  - brain parenchyma,
  - vessel lumen,
  - vessel wall.
- Noninvasive neuroimaging modalities provide less risk for a more conclusive understanding of the disease process
- « Invasive » cerebral angiography may be needed to image the intricate and at times, small involved vessels
- Neuroradiologists should be included in the multidisciplinary team of physicians caring for patients with vasculitis

# CNS vasculitis: parenchymal imaging

- MRI (>>> CT-scan)
- Micro or macro ischemia: subcortical and deep white matter, deep gray nuclei, and the cortices (T1, T2, Flair)
- Diffusion-weighted imaging (DWI) helps to distinguish acute, subacute, and chronic ischemia
- Lesions are frequently bilateral and of differing ages
  - >>>> clue of diagnosis suspicion
- Nonspecific white matter diffuse changes
- Micro or macro intra-parenchymal bleeding (T2\*)
- Focal subarachnoid hemorrhage
- Leptomeningeal enhancement
  - >>>> small vessel vasculitis
- Other MRI modalities: less contributive

*Younger, neurol clin, 2019*

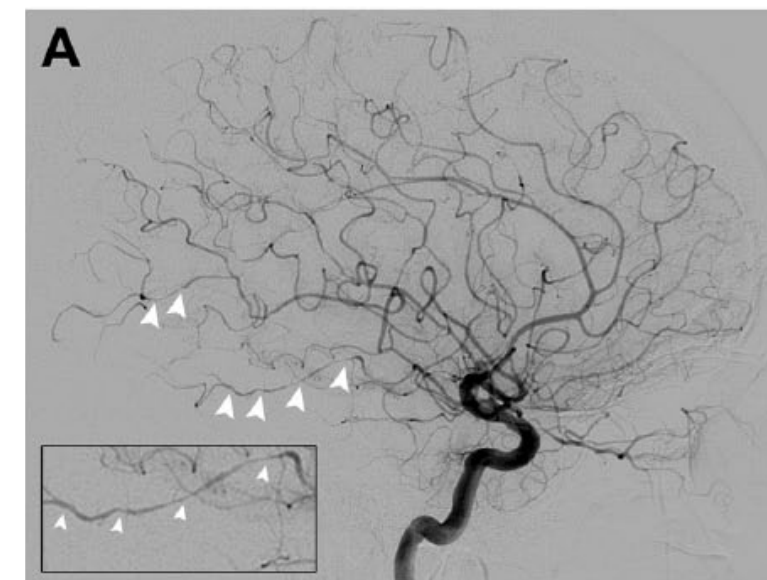
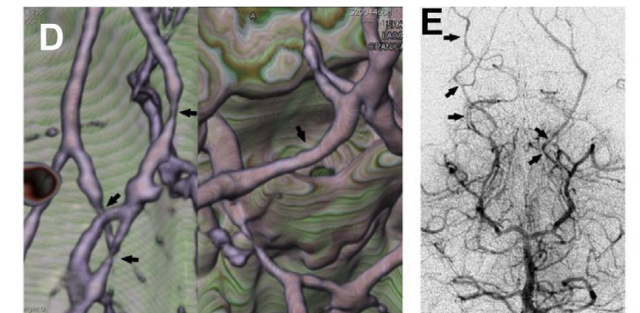
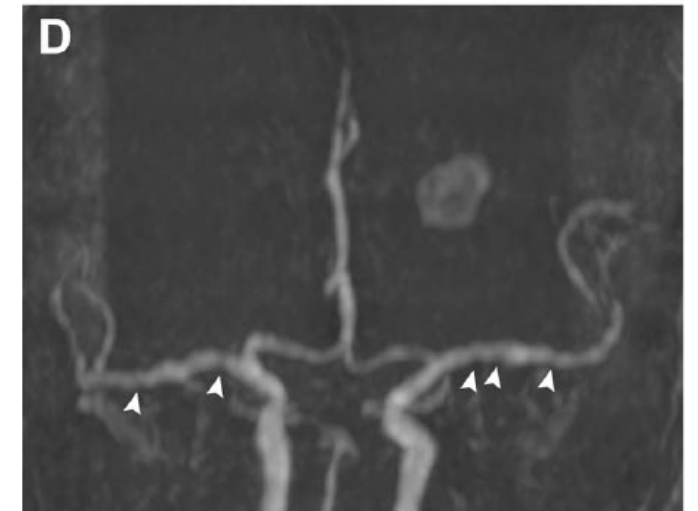


*Beuker et al., Ther Adv Neurol Disord, 2018*



# CNS vasculitis: vessel lumen imaging

- Angio (TOF) MRI, Angio CT-Scan, conventional angiography
- Spatial and temporal resolution of conventional angiography is currently the best of all imaging techniques in use
- Areas of narrowing and dilatation or multilocular occlusions of intracranial vessels
- Fusiform (post-stenotic) arterial dilatations
- Development of a collateral circulation, delayed contrast enhancement.
- Long segment stenoses, microaneurysms and complete occlusions: less frequent
- Angiography can be false-negative (vessels < 500µm)
- Etiologic orientation according to the size of the vessels affected and the distribution of lesions
- Even in the presence of classic angiographic findings, an alternative diagnosis is possible

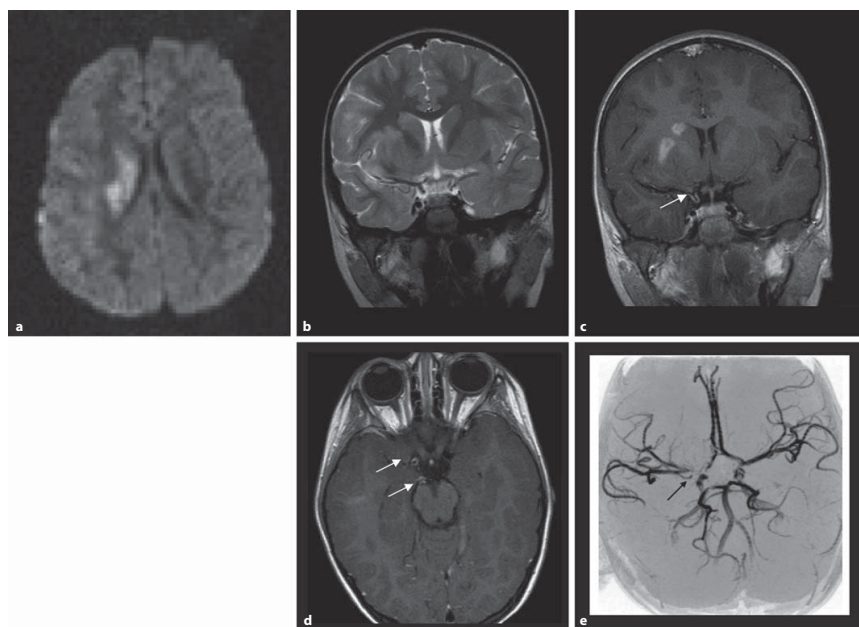


# CNS vasculitis: vessel wall imaging

## Vessel Wall Contrast Enhancement: A Diagnostic Sign of Cerebral Vasculitis

Wilhelm Küker<sup>a,b</sup> Susanne Gaertner<sup>c</sup> Thomas Nägele<sup>d</sup> Christian Dopfer<sup>e</sup>  
Martin Schöning<sup>e</sup> Jens Fiehler<sup>a</sup> Peter M. Rothwell<sup>b</sup> Ulrich Herrlinger<sup>f</sup>

Cerebrovasc Dis 2008;26:23–29



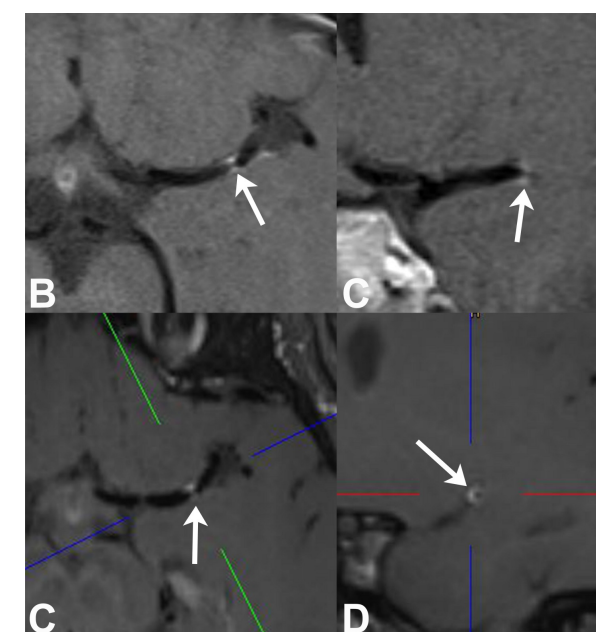
- 27 patients with a diagnosis of cerebral vasculitis
- Diagnosis was based on histological or serological proof of vasculitis or on clinical and imaging criteria.
- MRI scans were assessed for vessel wall thickening and contrast uptake
- Vessel wall thickening was identified in 25/27 patients
- Wall enhancement in 23/27 patients

>>>> Wall thickening and intramural contrast uptake are frequent findings in patients with active cerebral vasculitis affecting large brain arteries

High-resolution contrast-enhanced vessel wall imaging in patients with suspected cerebral vasculitis: Prospective comparison of whole-brain 3D T1 SPACE versus 2D T1 black blood MRI at 3 Tesla

PLOS ONE | <https://doi.org/10.1371/journal.pone.0213514> March 8, 2019

Sebastian Eiden<sup>1</sup>, Christopher Beck<sup>1,2</sup>, Nils Venhoff<sup>3</sup>, Samer Elsheikh<sup>1</sup>, Gabriele Ihorst<sup>4</sup>, Horst Urbach<sup>1</sup>, Stephan Meckel<sup>1\*</sup>



- HR-MRI such as ‘black blood MRI’ may be helpful in pathologic findings in and around the wall of intracranial vessels
- Differentiating between inflammation, intracranial atherosclerotic plaques, and other wall abnormalities based on the typical enhancement patterns was reported.
- Improvement of this emerging noninvasive technique should be a possible future perspective.
- An additional aim of future studies could be the implementation of nuclear medicine molecular diagnostic tools (Pet-scan)

# CNS vasculitis: CSF and biology

- CSF analysis reveals abnormal (inflammatory findings) in around half of patients with cerebral vasculitis (80–90% in PACNS)
- Mild lymphocytic pleocytosis / elevated protein level
- If normal CSF findings:
  - >>>> direct diagnostic work-up towards possible differential diagnoses
- Normal CSF and normal brain MRI:
  - >>>> CNS vasculitis can be ruled-out
- Some results are indicative for infectious origin of vasculitis (more than 250 cells/ $\mu$ l ; frank increase of proteins or decrease of glucose)
  - >>>> further analyses should include appropriate cultures, PCR and Ab indices
- Serum screening can show increased acute phase reactants (ESR/ serum CRP)
- Detection of antinuclear, antineutrophil cytoplasmic, antiphospholipid antibodies, rheumatoid factor, cryoglobulins or bacterial or viral antibodies is highly suggestive of an underlying systemic vasculitis or autoimmune disease.

# CNS vasculitis: Stepwise approach to diagnostic in routine practice

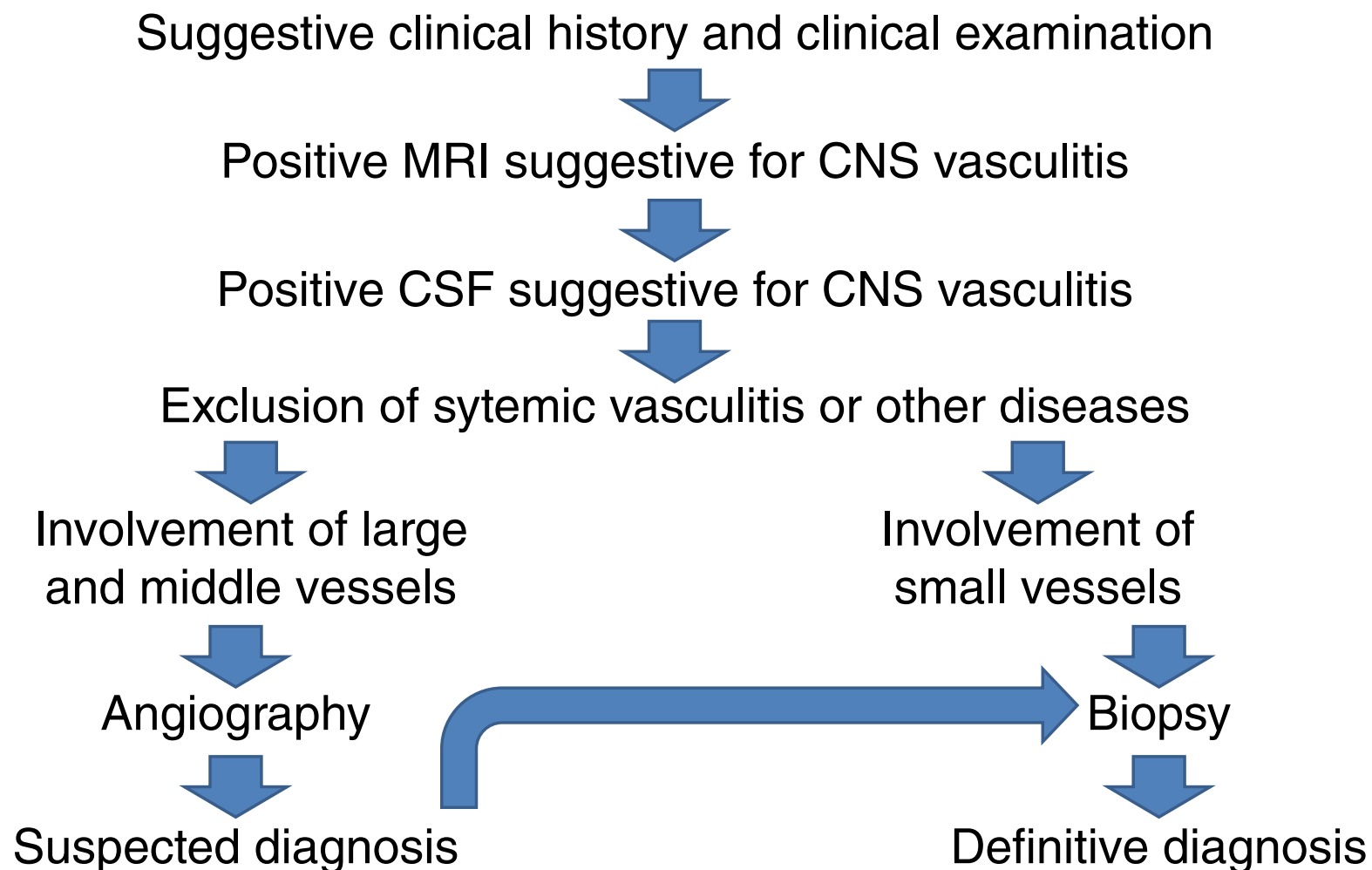
- Suggestive situations for diagnosis of CNS vasculitis
  - Clinical symptoms and signs
  - MRI (or CT scan) pattern of vascular mechanism
  - Inflammatory findings in CSF study
- Symptoms of (known or unknown) **systemic disease** (articular, skin, ophthalmic....)
- Digital arteriography
- Parenchymal and leptomeningeal biopsy
- Suggestive pattern to specific cause



# CNS vasculitis: Suggestive situations

- Cerebral ischemic episodes in different vascular beds, usually separated by time, with the presence of inflammatory changes in the CSF
- Cerebral ischemia in young patient with lack of traditional cerebrovascular risk factors for strokes
- Chronic meningitis without a demonstrated infectious or malignant etiology
- Subacute or chronic headache associated with cognitive dysfunction, usually with a history of aseptic meningitis
- Combination of unexplained focal and diffuse neurologic dysfunction

# CNS vasculitis: Steps to diagnostic approach in routine practice



## Differential diagnosis

+++

**\*\* Non vascular CNS diseases**  
(ADEM, infectious and dysimmune encephalitis....)

**\*\* Vascular non inflammatory CNS lesions**

- More frequent
- Atherosclerosis, cardioembolism events, Antiphospholipid Ab...
- Vasculitis « mimics »:

Reversible Cerebral Vasoconstriction Syndrome (RCVS) ; Small Infarcts of Chochlear, Retinal and Encephalic Tissues (SICRET) ; Sneddon syndroms, .....

# CNS vasculitis: Histology

- In patients with suspicion of CNS vasculitis but inconclusive imaging findings, brain biopsy for definite diagnosis is mandatory
  - >>>> In practice, the majority of situations concern PACNS
- Due to the focal and segmental distribution of the disease, the sensitivity of brain biopsy is between 53–74%:
  - >>>> Diagnostic yield can be increased by targeting areas of imaging abnormality (parenchymal **and** leptomeningeal tissue)
- A negative biopsy cannot rule out the diagnosis of cerebral vasculitis:
  - >>>>> but histopathological examination often results in alternative diagnoses
- Histopathological findings include:
  - Transmural inflammation, mononuclear infiltrate
  - granulomatous inflammation, lymphocytic cellular infiltrates, necrotizing vasculitis
  - Infectious agent?
  - Others:  $\beta$ -amyloid deposits.....

# Main causes of CNS vasculitis

- **Polyarteritis nodosa and ANCA associated vasculitis** (Microscopic polyangiitis, Wegener, Churg-Strauss):
  - Peripheral Nerve System (Mononeuritis multiplex) most prevalent than CNS
  - CNS vasculitis: 3% to 40%!!
  - Diagnostic made by: other organs disturbances (kidney, respiratory tract, skin...) + ANCA
- **Vasculitis associated with systemic collagen vascular disease: rare condition**
  - Systemic lupus erythematosus
  - Rheumatoid arthritis vasculitis
- **Vasculitis associated with infection** (acute bacterial meningitis, mycobacterial tuberculous, syphilis, borreliosis, varicella zoster virus...):
  - Stroke due to large/medium size vessel (asymmetrical) involvement (internal carotid, Willis circle...)
  - Diagnostic made by clinical context, CSF results, appropriate cultures, PCR and Ab indices
- **Primary Angiitis of the Central Nervous System**
  - Rare disease, challenge for neurologists
  - Affects mainly patients around 50 years
  - Heterogeneous group, frequently requiring biopsy for confirmation
  - The RCVS is the most important noninflammatory differential diagnosis
  - Often, treatment give good improvement, relapses in 25% of cases

# PACNS

Classification according to Giannini and colleagues, 2012

Subtype	Clinical features	MRI	Angiogram	Biopsy
<b>Angiogram -negative biopsy-positive</b>	cognitive impairment, greater CSF abnormalities, favourable response to treatment	meningeal and parenchymal enhancing lesions on MRI	negative	granulomatous pattern
<b>Amyloid-<math>\beta</math>-related cerebral angiitis (ABRA)</b>	older age, predominantly males, cognitive impairment	contrast-enhanced meningeal lesions	positive	granulomatous pattern with $\beta$ -amyloid deposition in vessel walls
<b>Meningeal enhancement in MRI</b>	predominantly males, cognitive impairment, rapid response to treatment	prominent leptomeningeal enhancement	negative	granulomatous pattern
<b>Spinal cord involvement</b>	spinal cord symptoms, cerebral manifestations usually present	enhanced spinal (especially thoracic) lesions	negative	necrotizing pattern
<b>Intracranial or subarachnoid haemorrhage</b>	predominantly women, favourable response to treatment	intracranial or subarachnoid haemorrhage	positive	necrotizing pattern
<b>Rapidly progressive</b>	aggressive disease course, less responsive to treatment, often fatal outcome	bilateral, multiple, vessel lesions and infarctions	positive	granulomatous or necrotizing pattern

# CNS vasculitis: treatment considerations

- Treatment must be rapidly active on inflammation (and etiology particularly infection if suspected)
- CNS Vasculitis in the course of antineutrophil cytoplasmic antibody-associated vasculitis or associated with systemic collagen vascular disease: treatment according to consensus (CNS vasculitis is considered as poor prognosis factor)
- Treatment recommendations for PACNS are mainly based on retrospective studies and expert opinions
- Current therapeutic regimens are adapted from those validated in systemic vasculitis on ground of pathologic concordance

# CNS vasculitis: treatment of PACNS

## **Induction therapy** (to achieve remission and avoid worse outcomes)

- Corticosteroids:
  - Oral prednisone
  - Methylprednisolone pulse IV (1000 mg daily for 3 to 5 days)
- Cyclophosphamide
  - Daily oral dose (2 mg/kg/day) or monthly IV pulse dose (e.g starting at 750 mg/m<sup>2</sup>)

## **Maintenance therapy** (to limit the risk of relapses and prevent long-term disabilities)

- Azathioprine
- Methotrexate
- Mycophenolate mofetil

## **Biological agents** (in some « rare » cases resistant to corticosteroids/cyclophosphamide)

- Rituximab
- Tumor necrosis factor-alpha blockers
- Infliximab
- Etanercept

# Conclusion and perspectives

- Clinical and neuroimaging features of CNS vasculitis are nonspecific.
- Diagnosing CNS vasculitis remains challenging (dilemma of angiography-negative vasculitis and false-negative brain biopsy)
- Vascular imaging advances (improvement of noninvasive technique of wall visualisation).
- Prospective and randomized treatment trials to define evidence-based strategies for the management of PACNS are needed



# References

1. Salvarani C, Brown RD Jr, Christianson T, Miller DV, Giannini C, Huston J 3rd, Hunder GG. An update of the Mayo Clinic cohort of patients with adult primary central nervous system vasculitis: description of 163 patients. *Medicine (Baltimore)*. 2015;94(21):e738.
2. Salvarani C, Brown RD Jr, Christianson TJH, Huston J 3rd, Morris JM, Giannini C, Hunder GG. Primary central nervous system vasculitis mimicking brain tumor: Comprehensive analysis of 13 cases from a single institutional cohort of 191 cases. *J Autoimmun*. 2019;97:22-28
3. Goertz C, Wegner C, Brück W, Berlit P. Primary angiitis of the CNS with pure spinal cord involvement: a case report. *J Neurol*. 2010;257(10):1762-4.
4. Younger DS. Imaging the Vasculitides. *Neurol Clin*. 2019;37(2):249-265.
5. Beuker C, Schmidt A, Strunk D, Sporns PB, Wiendl H, Meuth SG, Minnerup J. Primary angiitis of the central nervous system: diagnosis and treatment. *Ther Adv Neurol Disord*. 2018;9;11:1756286418785071.
6. Küker W, Gaertner S, Nagele T, Dopfer C, Schoning M, Fiehler J, Rothwell PM, Herrlinger U. Vessel wall contrast enhancement: a diagnostic sign of cerebral vasculitis. *Cerebrovasc Dis*. 2008;26(1):23-9.
7. Eiden S, Beck C, Venhoff N, Elsheikh S, Ihorst G, Urbach H, Meckel S. High-resolution contrast-enhanced vessel wall imaging in patients with suspected cerebral vasculitis: Prospective comparison of whole-brain 3D T1 SPACE versus 2D T1 black blood MRI at 3 Tesla. *PLoS One*. 2019;8;14(3):e0213514.
8. de Boysson H, Parienti JJ, Mawet J, Arquizan C, Boulouis G, Burcin C, Naggara O, Zuber M, Touzé E, Aouba A, Bousser MG, Pagnoux C, Ducros A. Primary angiitis of the CNS and reversible cerebral vasoconstriction syndrome: A comparative study. *Neurology*. 2018; 16;91(16):e1468-e1478.
9. de Boysson H, Arquizan C, Touzé E, Zuber M, Boulouis G, Naggara O, Guillevin L, Aouba A, Pagnoux C. Treatment and Long-Term Outcomes of Primary Central Nervous System Vasculitis. *Stroke*. 2018;49(8) 1946-1952.
10. Elbers J, Halliday W, Hawkins C, Hutchinson C, Benseler SM. Brain biopsy in children with primary small-vessel central nervous system vasculitis. *Ann Neurol*. 2010;68(5):602-10
11. Zheng Y, Zhang Y, Cai M, Lai N, Chen Z, Ding M. Central Nervous System Involvement in ANCA-Associated Vasculitis: What Neurologists Need to Know. *Front Neurol*. 2019;10;9:1166.
12. Salvarani C, Brown RD Jr, Muratore F, Christianson TJH, Galli E, Pipitone N, Cassone G, Huston J III, Giannini C, Warrington K, Hunder GG. Rituximab therapy for primary central nervous system vasculitis: A 6 patient experience and review of the literature. *Autoimmun Rev*. 2019;18(4):399-405.
13. Byram K, Hajj-Ali RA, Calabrese L. CNS Vasculitis: an Approach to Differential Diagnosis and Management. *Curr Rheumatol Rep*. 2018 30;20(7):37.